



Case Report | Cardiovascular

Multisystem Inflammatory Syndrome in Children due to COVID-19, Causing Giant Coronary Artery Aneurysms

Veenu John¹, S. Nithin Bharadwaj¹, Siddarthkumar Chawath¹, Girish Gururaja²

Departments of ¹Cardiology, ²Pediatrician and Neonatologist, Apollo BGS Hospitals, Mysuru, Karnataka, India.

***Corresponding author:**

Veenu John,
Department of Cardiology,
Apollo BGS Hospitals, Mysuru,
Karnataka, India.

veenu.remaliya@gmail.com

Received: 18 November 2024
Accepted: 17 October 2025
Epub Ahead of Print: 09 December 2025
Published:

DOI
10.25259/IJCDW_88_2024

Quick Response Code:



ABSTRACT

According to the Centers for Disease Control (CDC) health advisory may 2020, Multisystem Inflammatory Syndrome in Children (MIS-C) is defined as an individual <21yrs presenting with fever, laboratory evidence of inflammation and evidence of clinically severe illness requiring hospitalization with multisystem (≥ 2) organ involvement(cardiac, renal, respiratory, hematologic, gastrointestinal, dermatologic or neurological) and no alternative plausible diagnosis and Positive for current or recent SARS-CoV2 (COVID 19) infection by Reverse Transcription Polymerase chain Reaction (RT-PCR), serology or antigen test or COVID 19 exposure within the 4 weeks before the onset of symptoms and The most affected age group is 6–10 years. Fever meaning a temperature of $>38^{\circ}\text{C}$ for ≥ 24 hours or a report of subjective fever lasting ≥ 24 hours. Laboratory examination of changes in peripheral blood complete blood count (CBC) parameters during acute Kawasaki disease (KD) shows evidence of inflammation. CBC parameters were collected at the initial, pre-IVIG, and post-IVIG stages. The rank-sum test assessed parameter differences over time, including elevated C-reactive protein (CRP), erythrocyte sedimentation rate (ESR), fibrinogen, ferritin, procalcitonin, D-dimer, lactic acid dehydrogenase (LDH), elevated neutrophils, reduced lymphocytes, and low albumin.

Keywords: Coronary dilatation, Immunoglobulin therapy, Multisystem inflammatory syndrome, Post-COVID-19 vasculitis, Post-viral infection

INTRODUCTION

Children's multisystem inflammatory syndrome (MIS-C) is a dangerous illness linked to COVID-19. Eighty-two percent of the children with COVID-19 had mild symptoms According to the may 2020 CDC health advisory states that MIS-C is defined as a person under 21 who has a fever, laboratory evidence of inflammation, and signs of a clinically severe illness that requires hospitalization and involves multiple systems (≥ 2) organs "(cardiac, renal, respiratory, hematologic, gastrointestinal, dermatologic, or neurological)" and has no other valid diagnosis. They also have a positive result for a current or recent SARS-CoV2 (COVID 19) infection by reverse transcription polymerase chain reaction (RT-PCR), serology, antigen test, or COVID 19 exposure in the four weeks before symptoms appear.

CASE REPORT

A girl whose 2-year-old came in with a background of fever for 5-day duration with loose stools, vomiting, congested eyes, red, cracked lips, and strawberry tongue. The physical examination findings were unremarkable. Investigations revealed hemoglobin of 12 g, total leukocyte count of 5700 with lymphopenia (absolute lymphocyte count, 1254), platelet count (PLT) of 5.3 lac,

This is an open-access article distributed under the terms of the Creative Commons Attribution-Non Commercial-Share Alike 4.0 License, which allows others to remix, transform, and build upon the work non-commercially, as long as the author is credited and the new creations are licensed under the identical terms.

©2025 Published by Scientific Scholar on behalf of Indian Journal of Cardiovascular Disease in Women

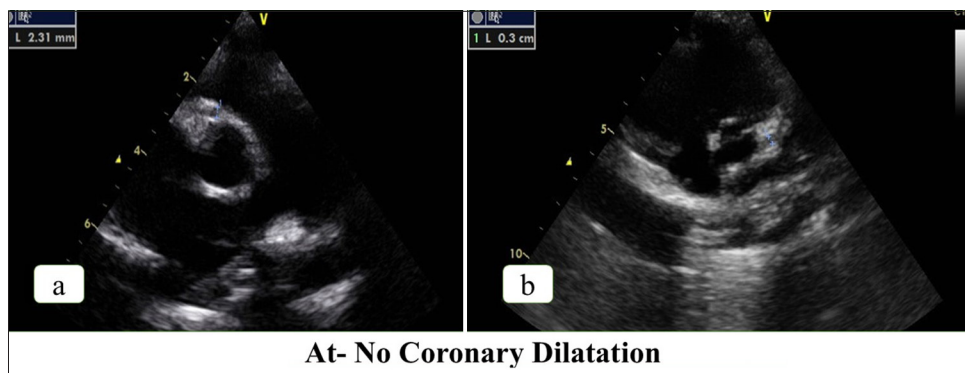


Figure 1: Transthoracic echocardiography of parasternal short-axis view-first visit (a) Right coronary artery, (b) Left main coronary artery.

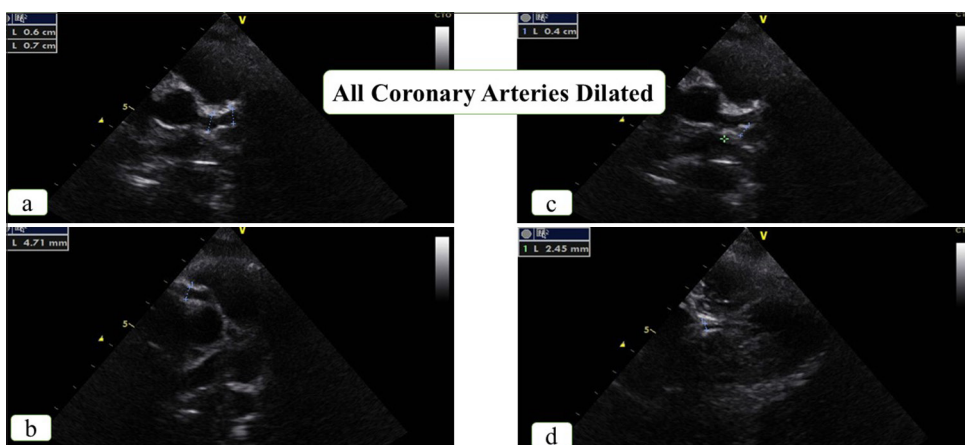


Figure 2: Transthoracic echocardiography of parasternal short-axis view-second visit (a) Left main coronary artery, (b) Left circumflex artery, (c) Proximal right coronary artery, (d) Distal right coronary artery.

Table 1: Z-Scores of coronary arteries.

Z-Scores of Coronary Arteries	Day 8 th Echocardiography		Day 19 th Echocardiography		One week after Intravenous Immunoglobulin Injection Echocardiography		One year post Admission	
	Diameter	Z Score	Diameter	Z Score	Diameter	Z Score	Diameter	Z Score
Coronary Arteries								
Left Main Coronary Artery (LMCA)	3.0mm	1.97mm	7.0mm	12.25mm	4.9mm	6.85mm	2.7mm	1.3mm
Left Anterior Descending (LAD)	2.3mm	1.00mm	6.0mm	11.87mm	2.9mm	3.35mm	2.6mm	2.5mm
Left Circumflex Coronary Artery (LCX)	2.0mm	0.84mm	4.0mm	5.88mm	2.5mm	2.07mm	2.1mm	1.2mm
Right Coronary Artery (RCA)	2.3mm	0.82mm	4.7mm	6.81mm	2.5mm	1.30mm	2.9mm	2.4mm
Distal Right Coronary Artery (dRCA)	2.0mm	0.94mm	2.4mm	2.12mm	2.0mm	1.02mm	1.8mm	0.7mm

erythrocyte sedimentation rate (ESR) of 88 at, COVID 19 immunoglobulin M (IgM), and immunoglobulin G antibodies were negative, C-reactive protein (CRP) of 68 mg/L, D Dimer of 5558 ng/mL, both, IgM Leptospira was negative, and urine routine showing pus cells but urine culture and blood culture showing no growth. The antistreptolysin O titer was negative. This occurred during the second COVID-19 wave in India in September 2021. The child had been exposed to COVID-19, with both the mother and father testing positive. The child's reverse transcription-polymerase chain reaction was also negative. Echocardiography was performed on day 8 of fever, which showed normal coronaries [Figure 1a-b] with Left Main Coronary Artery (LMCA) - 3.0 mm and Z score - 1.97 mm (1.47–3.0 mm), Left Anterior Descending (LAD) - 2.3 mm and Z score - 1.6 mm (1.02–2.43 mm), left circumflex coronary artery (LCX) - 2.0 mm and Z score - 0.84 mm (0.89–2.45 mm), right coronary artery (RCA) - 2.3 mm and Z score - 0.82 mm (1.19–2.76 mm), and Distal Right Coronary Artery (dRCA) - 1.96 mm and Z score - 0.94 mm (0.87–2.34 mm). Treatment for the patient included methylprednisolone, antibiotics, and aspirin. Fever settled on day 7 of treatment, with a reduction in inflammatory markers. At discharge on oral steroids and aspirin, the child had a CRP of 19.7 mg/L and D-dimer of 1217 ng/mL.

The child was afebrile for 3 days post-discharge but developed a fever again. On the 19th day of initial illness, repeat investigations showed features of raised inflammatory markers, with CRP at 36.9 mg/dL, ESR at 77 mm/h, total count at 17800 cells/cm³, and PLT at 10.6 lac. Echocardiography performed at this time revealed a coronary artery aneurysm of all three coronary arteries; both the left main and LAD coronary arteries have a massive coronary artery aneurysm [Table 1 and Figure 2a-d] with trace pericardial effusion.

She was immediately started on intravenous immunoglobulin (IVIG) infusion of 2 mg/kg for 5 days, methyl prednisolone, aspirin, heparin, and other supportive care. After IVIG infusion, repeat laboratory investigation showed improvements in parameters with hemoglobin (Hb):9.2 g%, CRP:2.9 mg/dL, ESR: 15 mm/h. Compared with pre-IVIG treatment, post-IVIG treatment has shown gross improvement in the laboratory investigations. The percentage of lymphocytes, eosinophils, and PLT significantly increased after IVIG treatment, while the percentage of neutrophils, red blood cell count, Hb, platelet distribution width, CRP, neutrophil-to-lymphocyte ratio, platelet-to-lymphocyte ratio, and mean platelet volume-to-lymphocyte ratio significantly decreased.^[1] Echocardiography performed after 1 week revealed a reduction in the z-scores, and she was discharged [Figure 3a-b].

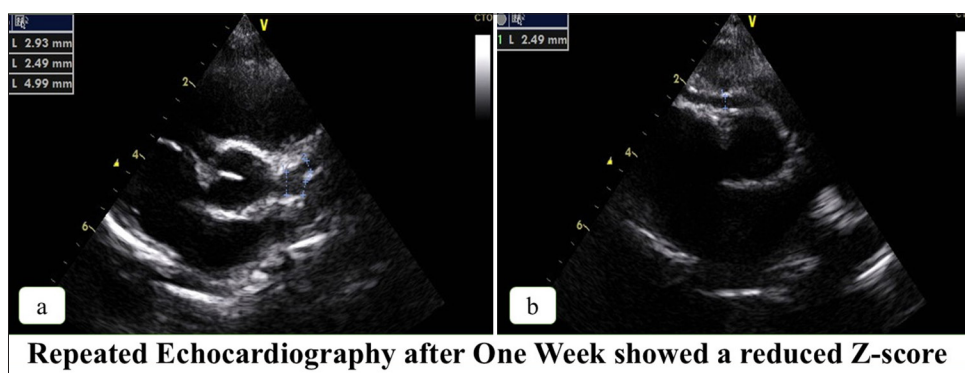


Figure 3: Transthoracic echocardiography of parasternal short-axis view– after intravenous immunoglobulin infusion (a) Left main coronary artery, (b) Right coronary artery.

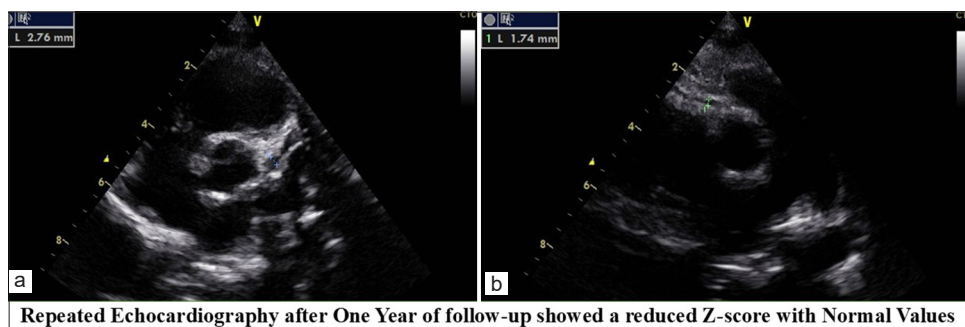


Figure 4: Transthoracic echocardiography of parasternal short-axis view-1-year follow-up (a) Left main coronary artery, (b) Right coronary artery.

Repeat echocardiography showed a reduction in the Z-scores, with normal values at 1 year [Figure 4a-b]. Although the sizes were normal, there were irregularities in the LAD; hence, aspirin was continued. At 2 years follow-up, the LAD showed an area of discrete dilatation in the proximal segment of 4 mm (z score -6.15) which was new compared to the previous study. At the 30-month follow-up, echocardiography was performed to reveal z-scores. The patient was asymptomatic. Aspirin was continued, and the child was advised to undergo computed tomography (CT) coronary angiography.

DISCUSSION

Children's multisystem inflammatory syndrome (MIS-C) is a dangerous illness linked to COVID-19. Eighty-two percent of the children with COVID-19 had mild symptoms, while the remaining children showed no symptoms at all. In children who are genetically vulnerable, the pathophysiology of MIS-C is believed to be caused by a hyperimmune reaction to the virus. MIS-C occurred in 4.9% of children, with a low death rate of 2.7%. Up to 67–80% of individuals with MIS-C experience cardiac involvement, which is more prevalent in MIS-C than in Kawasaki disease (KD).^[2] Cardiac manifestations may be in the form of myocarditis (disproportionate tachycardia, left ventricular dysfunction), conduction system abnormalities, and coronary artery aneurysms.^[3] The coronary artery involvement varies from 6 to 24% of cases.^[4] Giant coronary artery aneurysms (Z score >10 or diameter >8 mm) are rare.^[4]

The patient, a 2-year-old girl, had multisystem inflammatory symptoms. While KD is associated with age, the following characteristics set KD apart: Gastrointestinal symptoms, initial lymphopenia, elevated D-dimer levels, exposure to COVID-19 infection, and lack of hand or foot swelling. The MIS-C/KD discrimination score was 73 points (CRP >11 mg/dL (18points) + D Dimer >607 ng/mL (27points) + gastrointestinal involvement (28 units), favoring MIS-C.^[5] MIS-C was the child's diagnosis and was started on treatment with high-dose corticosteroids with antibiotics and aspirin.^[6,7] Despite initial improvement, the child had a recurrence of fever, and a repeat echocardiography revealed a giant coronary artery aneurysm involving the LMCA and the LAD artery with z-scores of 12.25 and 11.87, respectively.^[8] With z-scores of 5.88 and 6.81, respectively, both the RCA and the LCX were aneurysmal. Giant coronary artery aneurysms in MIS-C with involvement of all three coronary arteries are rare.^[9] The child was started on IVIG and high-dose corticosteroids with dual antiplatelets and unfractionated heparin according to weight (activated partial thromboplastin time being monitored). The child responded to this treatment, and the coronary artery sizes reduced at 1-week post-treatment and normalized by 1 year. The aspirin was continued^[2,8,9,10] because of slight abnormalities in the proximal segment of the LAD artery. At

2-year follow-up, although the sizes of the LAD artery and left circumflex artery remained stable, there was a region of discrete dilatation in the proximal LAD (4 mm, Z score 6.15). Despite the suggestion of a CT coronary angiogram from the beginning, there was no consent from the parents. Hence, the child was continued on low-dose aspirin. The occurrence of new coronary artery aneurysms during convalescence has been reported in MIS-C.^[11] In this instance, the development of new aneurysms after 2 years calls for additional research and long-term monitoring, similar to that of Kawasaki illness.

Study highlights

- Proximal coronary artery dilatation was well appreciated through transthoracic echocardiography, documented before and after treatment
- We should be more suspicious of vasculitides whenever there is a recurrent history of fever in children.

CONCLUSION

MIS-C is a severe side effect of COVID-19. In this instance, aneurysms of the left circumflex and right coronary arteries, as well as massive coronary artery aneurysms of the LMCA and LAD artery, were found in a child's case. Despite a good response to treatment initially, with normal sizes at 1 year of age. New aneurysms appeared at the 2-year follow-up in an asymptomatic child. This suggests that long-term follow-up of patients with MIS-C and coronary involvement is necessary. Long-term aspirin therapy is required for these patients. Since this is a new disease starting in mid-2020, only long-term studies will shed more light on the factors leading to progressive disease.

Ethical approval: Institutional Review Board approval is not required.

Declaration of patient consent: Patient's consent is not required as there are no patients in this study.

Financial support and sponsorship: Nil.

Conflicts of interest: There are no conflicts of interest.

Use of artificial intelligence (AI)-assisted technology for manuscript preparation: The authors confirm that there was no use of artificial intelligence (AI)-assisted technology for assisting in the writing or editing of the manuscript and no images were manipulated using AI.

REFERENCES

1. Fang X. The Clinical Value of Dynamic Monitoring of Complete Blood Count in Predicting Immunoglobulin Resistance in Chinese Children with Kawasaki Disease. *Sci Rep* 2025;15:18041.
2. Krishnamurthy S, Kar SS, Dhodapkar R, Parameswaran N. Comparison of COVID-19 Infection in Children during the First and Second Wave. *Indian J Pediatr* 2022;89:1016-8.
3. Feldstein LR, Tenforde MW, Friedman KG, Newhams M,

- Rose EB, Dapul H, *et al.* Characteristics and Outcomes of US Children and Adolescents with Multisystem Inflammatory Syndrome in Children (MIS-C) Compared with Severe Acute COVID-19. *JAMA* 2021;325:1074-87.
4. Sperotto F, Friedman KG, Dionne A, Son MB, VanderPluym CJ, Newburger JW. Cardiac Manifestations in SARS-CoV-2-Associated Multisystem Inflammatory Syndrome in Children: A Comprehensive Review and Proposed Clinical Approach. *Eur J Pediatr* 2021;180:307-22.
 5. Kostik MM, Bregel LV, Avrusin IS, Dondurei EA, Matyunova AE, Efremova OS, *et al.* Distinguishing between Multisystem Inflammatory Syndrome, Associated with Covid-19 in Children and the Kawasaki Disease: Development of Preliminary Criteria Based on the Data of the Retrospective Multicenter Cohort Study. *Front Pediatr* 2021;9:787353.
 6. Villacis-Nunez DS, Hashemi S, Nelson MC, Flanagan E, Thakral A, Rodriguez F 3rd, *et al.* Giant Coronary Aneurysms in Multisystem Inflammatory Syndrome in Children Associated with SARS-CoV-2 Infection. *JACC Case Rep* 2021;3:1499-508.
 7. Dufort EM, Koumans EH, Chow EJ, Rosenthal EM, Muse A, Rowlands J, *et al.* Multisystem Inflammatory Syndrome in Children in New York State. *N Engl J Med* 2020;383:347-58.
 8. Whittaker E, Bamford A, Kenny J, Kaforou M, Jones CE, Shah P, *et al.* Clinical Characteristics of 58 Children with a Pediatric Inflammatory Multisystem Syndrome Temporally Associated with SARS-CoV-2. *JAMA* 2020;324:259-69.
 9. Rowley AH. Understanding SARS-CoV-2-Related Multisystem Inflammatory Syndrome in Children. *Nat Rev Immunol* 2020;20:453-4.
 10. Consiglio CR, Cotugno N, Sardh F, Pou C, Amodio D, Rodriguez L, *et al.* The Immunology of Multisystem Inflammatory Syndrome in Children with COVID-19. *Cell* 2020;183:968-81.e7.
 11. Ahmed M, Advani S, Moreira A, Zoretic S, Martinez J, Chorath K, *et al.* Multisystem Inflammatory Syndrome in Children: A Systematic Review. *EClinicalMedicine* 2020;26:100527.

How to cite this article: John V, Bharadwaj SN, Chawath S, Gururaja G. Multisystem Inflammatory Syndrome in Children due to COVID-19, Causing Giant Coronary Artery Aneurysms. *Indian J Cardiovasc Dis Women*. doi: 10.25259/IJCDW_88_2024