

Images in Cardiology Cardiovascular

Revisiting Supraventricular Tachycardia Maneuvers: A Pictorial Brief for the Budding Electrophysiologists

Atul Kaushik¹, Aparna Jaswal¹

¹Department of Cardiology, Fortis Escorts Heart Institute, New Delhi, India.

*Corresponding author:

Atul Kaushik,
 Department of Cardiology,
 Fortis Escorts Heart Institute,
 New Delhi, India.
dratulkaushik0126@gmail.com

Received: 25 April 2024
 Accepted: 29 May 2024
 Epub Ahead of Print: 29 June 2024
 Published: 30 December 2024

DOI

10.25259/IJCDW_27_2024

Quick Response Code:



A 65-year-old male known case of paroxysmal supraventricular tachycardia and left ventricular ejection fraction 55% presented with increased episodes of palpitations for 2 weeks in the emergency department. His electrocardiogram (ECG) revealed supraventricular tachycardia (SVT) at ventricular rate of 138/min, as shown in Figure 1. He was planned for electrophysiological study (EP) and radiofrequency ablation with 2-D mapping. The ECG gave a clue to the underlying mechanism of the tachycardia.

EP study revealed the mechanism to be atrioventricular nodal reentry tachycardia (AVNRT). [Figures 2-4] depict the various SVT maneuvers to establish the diagnosis of AVNRT.

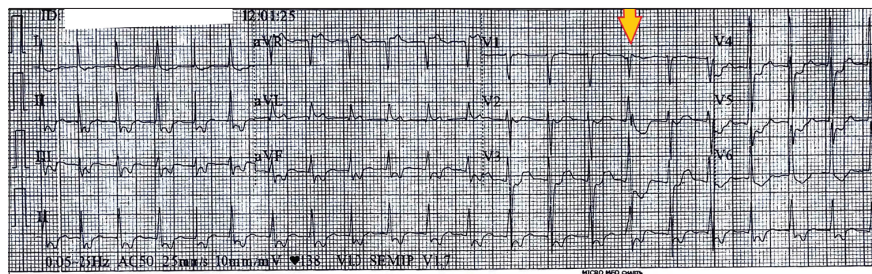


Figure 1: 12 lead Electrocardiogram of the patient showing a narrow complex tachycardia with short RP interval. The ventricular premature complex as marked by an arrow in leads V1-V3 shows that tachycardia cycle length is unaffected by it giving a clue to the mechanism of tachycardia could be atrioventricular nodal reentry tachycardia.

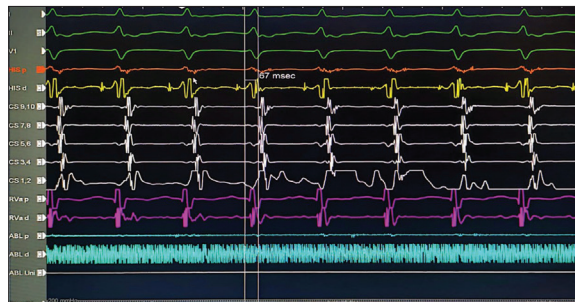

Figure 2: Tachycardia induction in the electrophysiological laboratory: Septal ventriculoatrial <70 ms is suggestive of typical atrioventricular nodal reentry tachycardia.

This is an open-access article distributed under the terms of the Creative Commons Attribution-Non Commercial-Share Alike 4.0 License, which allows others to remix, transform, and build upon the work non-commercially, as long as the author is credited and the new creations are licensed under the identical terms.
 ©2024 Published by Scientific Scholar on behalf of Indian Journal of Cardiovascular Disease in Women

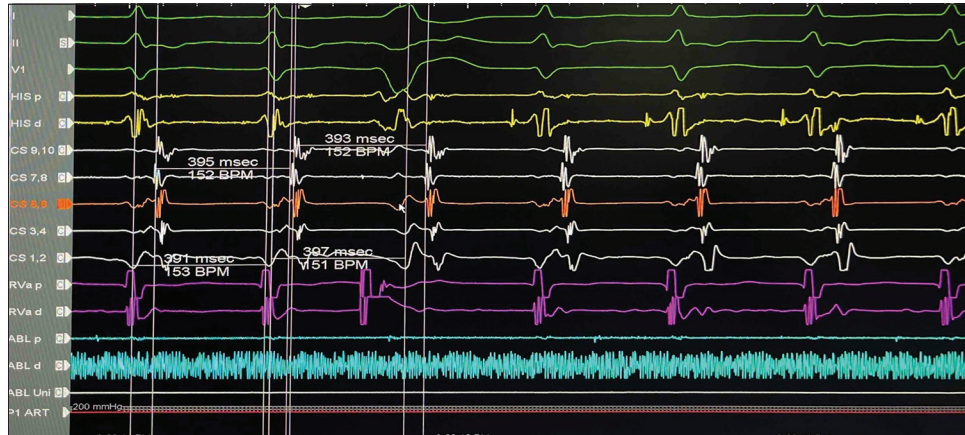

Figure 3: His synchronous premature ventricular contraction (PVC): The His synchronous PVC failed to reset the tachycardia as the tachycardia cycle length in the atrial electrogram is unchanged. Atrioventricular reentry tachycardia is less likely to be the mechanism.

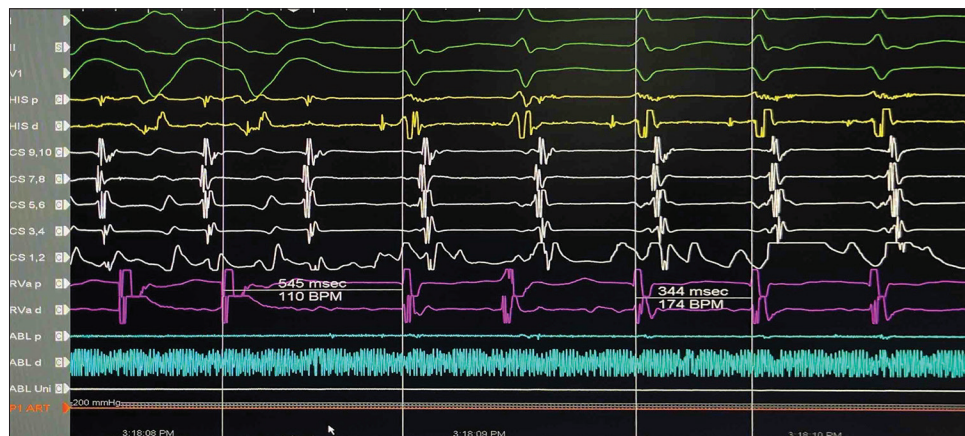

Figure 4: Entrainment during tachycardia: On cessation of ventricular pacing, the post-pacing interval minus tachycardia cycle length was 201 ms which is higher than 115 ms. This goes in favor of atrioventricular nodal reentry tachycardia (AVNRT). Further, the delta ventriculoatrial during V pacing and during tachycardia are more than 85 msec, favoring the mechanism to be AVNRT. Repetitive Entrainment episodes via V pacing during the Tachycardia documented VA linking, thus make sAT unlikely.

Radiofrequency modification of the slow pathway was done. Procedure was completed without any complication and he was discharged the next day.

Ethical approval

Institutional Review Board approval is not required.

Declaration of patient consent

The authors certify that they have obtained all appropriate patient consent.

Financial support and sponsorship

Nil.

Conflicts of interest

There are no conflicts of interest.

Use of artificial intelligence (AI)-assisted technology for manuscript preparation

The authors confirm that there was no use of artificial intelligence (AI)-assisted technology for assisting in the writing or editing of the manuscript and no images were manipulated using AI.

How to cite this article: Kaushik A, Jaswal A. Revisiting Supraventricular Tachycardia Maneuvers: A Pictorial Brief for the Budding Electrophysiologists. Indian J Cardiovasc Dis Women. 2024;9:249-50. doi: 10.25259/IJCDW_27_2024