

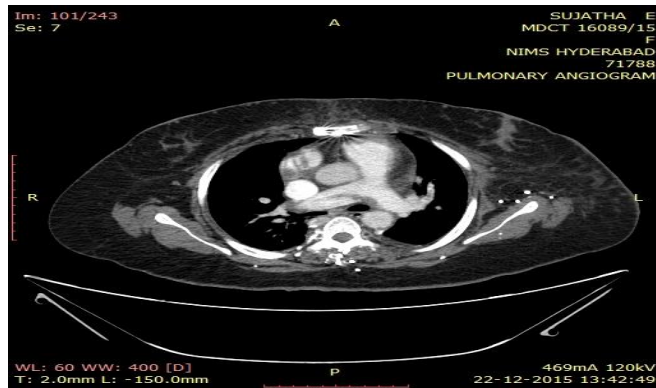
WCC 2016-112 : A case of varied presentation of thrombus: Ravi Kiran.

Abstract :

Antiphospholipid syndrome is a well defined entity that is characterized by spontaneous abortion , thrombocytopenia , and recurrent arterial and venous thromboses. A right atrial thrombus mimicking myxoma with pulmonary thromboembolism in a patient with secondary antiphospholipid syndrome is rare.

Herein , we describe the case of a 35 year old woman who was admitted to the hospital with shortness of breath, swelling of both lower limbs. Transthoracic and transesophageal echocardiography showed a right atrial mass suggestive of myxoma , and the patient subsequently underwent surgery. A histologic examination of the mass showed myxoma. In our patient , the preoperative investigations could not differentiate the thrombus from a myxoma , and she was operated in outside hospital. Later she presented with deep vein thrombosis and pulmonary thromboembolism to our hospital and was diagnosed as having secondary antiphospholipid syndrome and the review slides of the right atrial mass showed thrombus. Intracardiac thrombus has been rarely reported as a complication of antiphospholipid syndrome.

Case report : In December 2015, a 35 year old woman was admitted to the hospital with swelling of both lower limbs since 15 days , shortness of breath since 15 days. She had a past history of acute left upper limb ischemia in 15/4/2013 for which catheter directed thrombolysis of brachial artery was done with streptokinase, coronary angiogram showed normal coronaries. History of cervical TB lymphadenitis for which she used ATT for 9 months in 2013. History of excision of right atrial myxoma was done on 3/11/15 at outside hospital. Histologic examination showed myxoma . Patient has pallor and bilateral pedal edema on general examination. At admission vitals were stable and systemic examination was normal except for raised jugular venous pressure. ECG showed T inversions in leads V 3-6 ,II,III,aVF . 2D ECHO showed dilated RA/RV severe TR , moderate PAH , RVSP 50 mm of Hg , TAPSE 1.3 , good LV function, mild RV dysfunction , mobile thrombus at the junction of middle hepatic vein & IVC . CTPA showed saddle thrombus in PA extending into RPA , multiple collaterals in anterior & posterior chest wall with non visualisation of part of left subclavian vein.



Anti cardiolipin antibodies IgM was positive , IgG was negative. ANA was 2+(dsDNA , histone was positive). B/L lower limb venous doppler showed partial thrombosis involving left CFV & proximal left SFV. B/L upper limb arterial & venous doppler was normal. Hb % was 6.3 with microcytic hypochromic picture. NTproBNP was 1278 pg/ml. TSH was 6.1. Review slides of the right atrial mass at our hospital showed thrombus.

Final diagnosis is dvt left lower limb, pte with moderate pah with thrombus at ivc & ra junction, unclassified connective tissue disorder, antiphospholipid antibody syndrome. Patient was treated with anticoagulation , blood transfusion , diuretics. Patient was discharged in a stable condition and is under follow up.