

WCC 2017-C-111: ANAMOLOUS ORIGIN OF RCA

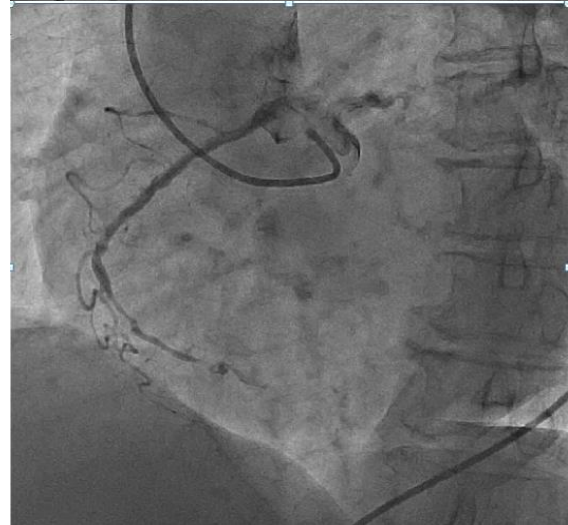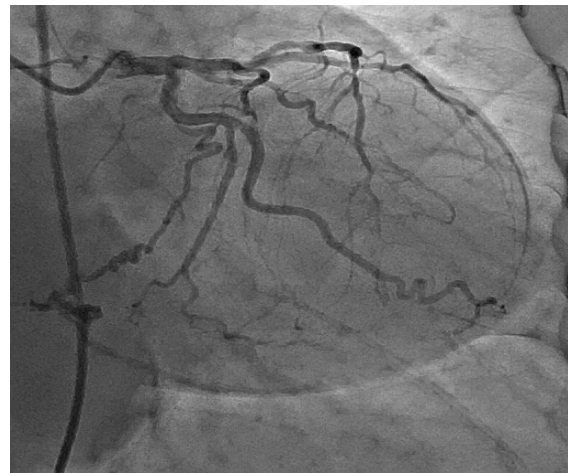
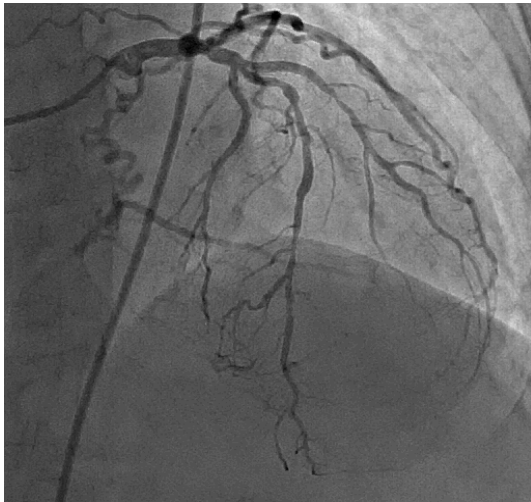
A. Siva Rama Krishna

Adinarayanamma 66y of age diagnosed as CAD with NSTEMI, ECG shown ST depressions inferior leads 2d echo shows hypokinesia in RCA & LAD territory & mild lv systolic dysfunction.

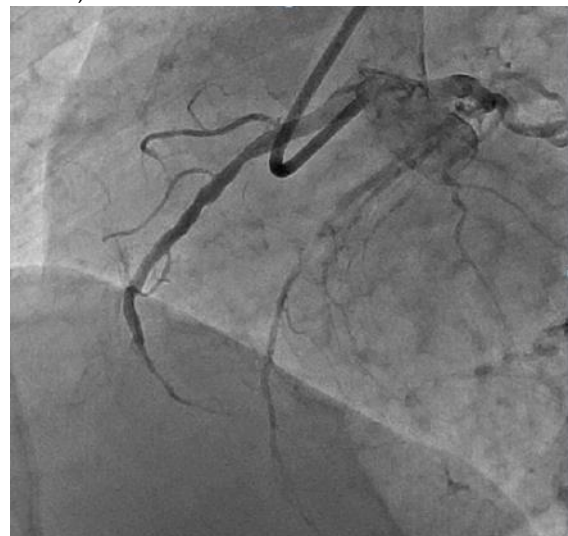CAG shown LAD distal 80%, LCX Normal, RCA Anomalous origin from left sinus showing mid to distal 90% - 96% lesion, distal vessel filling from the left segment.

RCA was engaged with 6f EBU 3.0 lesion was crossed with PILOT50 0.014* 190cm, Pre dilated with 1.5*8 mm & 2.*12 mm, scented with indolimus 2.5*36 (DES) Post dilatation 2.5*12 mm Post stenting TIMI II flow acquired.

CAG



Guide-ebu 3.0, 6F WIRE-PILOT 50, 0.014-190 CM
BMW, 0.014-190 CM



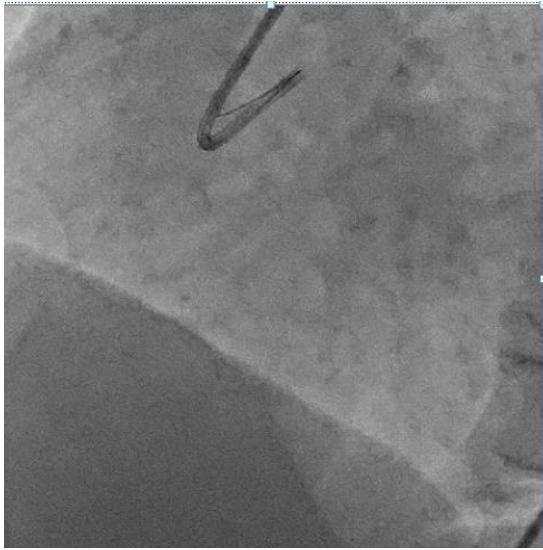
Article received on 25 FEB 2017, published on 08 MAR 2017.

A. Siva Rma Krishna¹

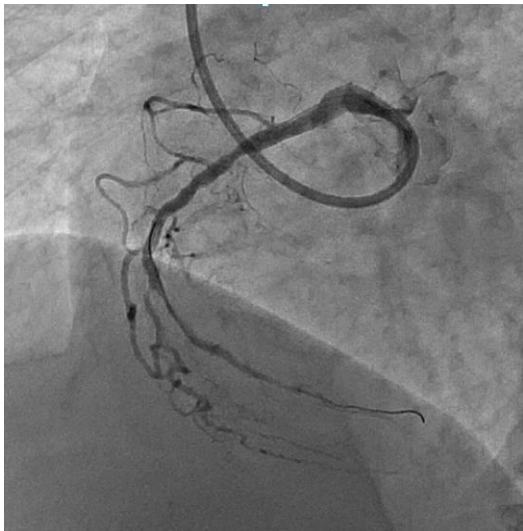
¹Assistant Professor, Department of Cardiology, Guntur Medical College, India

Corresponding Author: A. Siva Rama Krishna

Email: drsrkarikeri@gmail.com



PREDILATATION-1.5*8mm2*12mm



Indolimus -2.5*36mm
Post dilatation-NC TREK 2.5*12mm

