

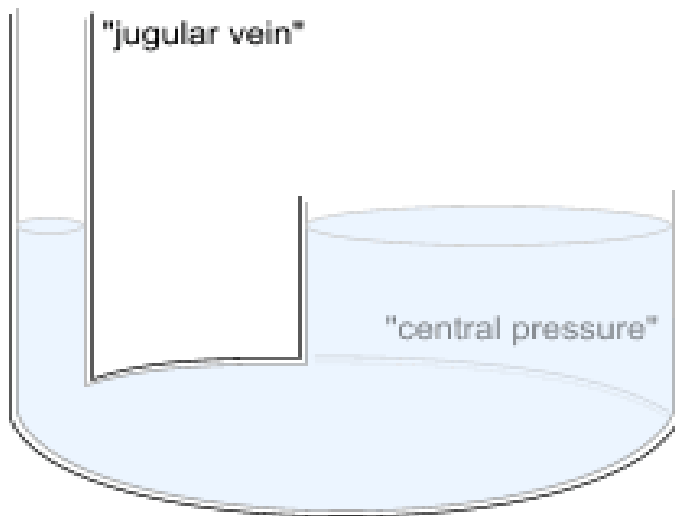
JVP- JUGULAR VENOUS PRESSURE

Maddury Jyotsna

DEFINITION OF JUGULAR VENOUS PULSE AND PRESSURE

Jugular venous pulse is defined as the oscillating top of vertical column of blood in the right Internal Jugular Vein (IJV) that reflects the pressure changes in the right atrium in cardiac cycle. In other words, Jugular venous pressure (JVP) is the vertical height of oscillating column of blood (Fig 1).

Fig 1: Schematic diagram of JVP



NECK VEIN OF CHOICE FOR JVP MEASUREMENT

Right internal jugular neck vein should be used to test the JVP because the right internal jugular vein communicates directly with the right atrium via the superior vena cava. Even though there is a functional valve at the junction of the internal jugular vein and the superior vena cava, usually, this valve does not impede the phasic flow of blood to the right atrium. Thus the wave form generated by phasic flow to the right atrium is accurately reflected in the internal jugular vein. The relatively direct line between the right external and internal jugular veins, as compared to the left external and internal jugular veins, make the right jugular vein the preferred system for assessing the venous pressure and pulse contour.

Article received on 24APR 2017, published on 30 APR 2017.

Maddury Jyotsna¹

¹Professor & HOU-IV, Department of Cardiology, NIMS, India

Corresponding Author: Maddury Jyotsna

Email: mail2jyotsna@rediffmail.com

The external jugular vein descends from the angle of the mandible to the middle of the clavicle at the posterior border of the sternocleidomastoid muscle. The external jugular vein possesses valves that are occasionally visible. Blood flow within the external jugular vein is nonpulsatile and thus cannot be used to assess the contour of the jugular venous pulse.

Reasons for Internal Jugular Vein (IJV) preferred over other neck veins are IJV is anatomically closer to and has a direct course to right atrium while EJV does not directly drain into Superior vena cava. It is valve less and pulsations can be seen. Due to presence of valves in External Jugular vein, pulsations cannot be seen.

Vasoconstriction secondary to hypotension (as in congestive heart failure) can make EJV small and barely visible. EJV is superficial and prone to kinking.

Partial compression of the left innominate vein is usually relieved during modest inspiration as the diaphragm and the aorta descend and the pressure in the two internal jugular veins becomes equal. However, partial obstruction of the left innominate vein from compression by the aorta may persist, particularly in relatively elderly patients, impairing transmission of right atrial pressure to the left internal jugular vein; this is also the most common cause of unequal pressures between right and left internal jugular veins. There is better transmission of right atrial pressures and pulses to the right internal jugular vein since the right innominate and internal jugular veins are in a direct line with the superior vena cava. Thus, examination of the right internal jugular venous pulse is preferable for assessing the hemodynamic changes in the right side of the heart.

EVALUATION OF JVP

We have to describe the JVP under following headings

- Level
- Waveform
- Respiratory variation in level and wave pattern
- Hepato-jugular reflux
 - Venous hum

- Liver size and pulsations

Information that can be derived from an assessment of the jugular venous pulse includes

- 1. Determination of the mean venous pressure
- 2. Venous pulse contour
- 3. Presence and type of cardiac dysrhythmias.

METHOD TO CALCULATE THE LEVEL AND MEAN COLUMN OF JVP

The height of the mean jugular venous pressure which is measured in centimeters of water is the level of JVP above the midpoint of the right atrium. The midpoint of the right atrium is a constant fixed relationship (i.e., 5 cm) below the sternal angle of Louis regardless of the patient's anatomic position. Thus, whether the patient is lying flat or sitting erect, this anatomic relationship holds true.

To determine the mean jugular venous pressure, the examiner should observe the nadir of the venous column on inspiration and then the crest of this column on expiration. Next, the midpoint of the excursion of the venous pulse during normal respiratory cycles is estimated visually. Exaggerated breathing or breath holding distorts the normal mean venous pressure and should be avoided.

STEPS (PRECAUTIONS ALSO) IN MEASUREMENT OF JVP

- 1) Patient reclining with head elevated 45°
 - Measure elevation of neck veins above the sternal angle (Lewis Method).
 - Add 5 cm to measurement since right atrium is 5 cm below the sternal angle.

Normal CVP \leq 8 cm

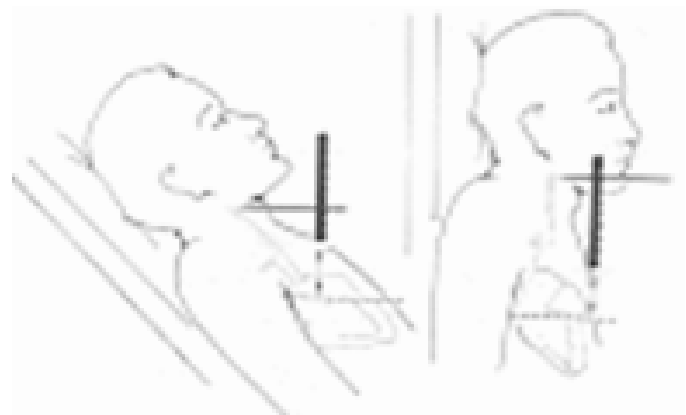
- 2) Light should be tangential to illuminate highlights and shadows.
- 3) Neck should not be sharply flexed.
- 4) Using a centimeter ruler, measure the vertical distance between the angle of Louis (manubrio sternal joint) and the highest level of jugular vein pulsation. A straight edge intersecting the ruler at a right angle may be helpful.

Note: Ability to measure jugular venous pressure will be difficult if pulse is 100 per minute.

- 5) If the intimal jugular vein is not detectable, use the external jugular vein. The internal jugular vein is the preferred site.

A horizontal line is drawn from this estimated point to intersect a vertical line, which is erected perpendicular to the ground through the sternal angle of Louis. The distance between the sternal angle and this intercept is measured (Fig 2).

Fig 2: Demonstration to determine the height of the mean jugular venous pressure



The sum of this distance-plus the obligatory 5-cm fixed relationship to the midpoint of the right atrium-represents the mean jugular venous pressure.

Assuming that the top of the venous column has been observed, the degree of the patient's inclination from horizontal does not have to be stated. While a ruler may be used to measure the distance between the intercept and the sternal angle of Louis, this appliance may not always be readily available. If the width of the observer's fingers is known, these may serve the same purpose. Normally, the mean venous pressure falls during inspiration. It is especially important that the patient does not perform a Valsalva maneuver or hold his breath during this procedure.

Table 1: Distinguishing the internal jugular vein pulsations from the carotid artery pulsations.

Jugular Vein	Carotid Artery
No pulsations palpable.	Palpable pulsations.
Pulsations obliterated by pressure above the clavicle.	Pulsations not obliterated by pressure above the clavicle.
Level of pulse wave decreased on inspiration; increased on expiration.	No effects of respiration on pulse.
Usually two pulsations per systole (x and y descents).	One pulsation per systole.
Prominent descents. Has effect of abdominal pressure on pulsations.	Descents not prominent. No effect of abdominal pressure on pulsations.

IDENTIFICATION OF WAVES IN JVP

The normal jugular venous pulse contains three positive waves. By convention, these are labeled "a," "c," and "v". These positive deflections occur, respectively, before the carotid upstroke and just after the P wave of the ECG (a wave); simultaneous with the upstroke of the carotid pulse (c wave); and during ventricular systole until the tricuspid valve opens (v wave) (Fig 3, 4).

Fig 3: Corresponding components of JVP, ECG, Carotid pulse and heart sounds.

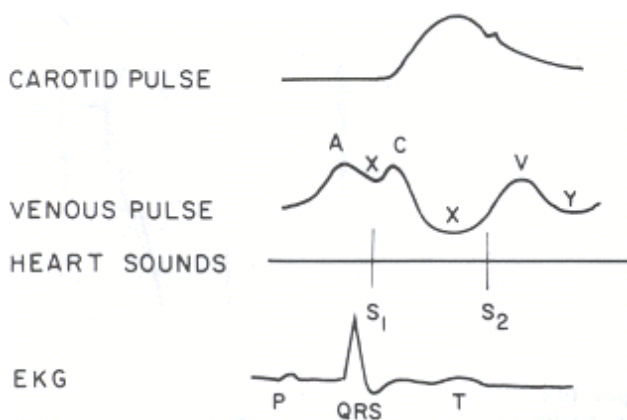
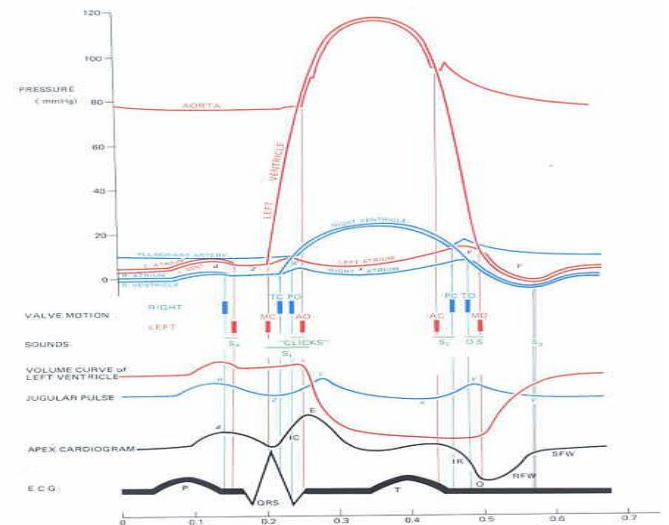


Fig 4: Correlation of JVP with intracardiac pressures and heart sounds.



“h” wave between the bottom of ‘y’ descent and beginning of ‘an’ ascent, during the period of diastase is (relatively slow ventricular filling).

The best way to identify the waves (ascents and descents) would be to simultaneously auscultate and observe the wave pattern (Fig 3,4).

- ‘a’ ascent: clinically corresponds to S1 (though it actually occurs before S1); sharper and more prominent than ‘v’ wave.
- ‘x’ descent follows S1.
- ‘c’ ascent: occurs simultaneously with carotid pulse, but never seen normally.
- ‘v’ ascent: coincides with S2; less prominent than ‘a’ ascent.
- ‘y’ descent: follows S2.

The a wave is generated by atrial contraction, which actively fills the right ventricle in end-diastole. The c wave is caused either by transmission of the carotid arterial impulse through the external and internal jugular veins or by the bulging of the tricuspid valve into the right atrium in early systole. The v wave reflects the passive increase in pressure and volume of the right atrium as it fills in late systole and early diastole (Table 2).

Table 2: Difference between “a” and “v” waves.

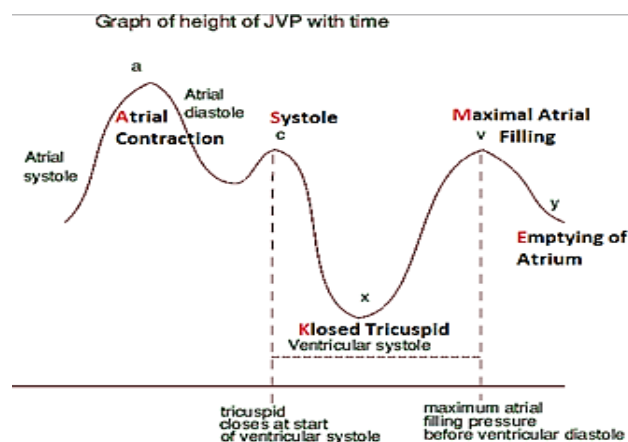
	A wave	V wave
Mechanism	Active contractile wave	Passive filling wave
Timing	Pre-systole (S1)	End systole (S2)
Height	Tall	less tall
Duration	Brief	Sustained
Morphology	Flicker	Blunted
Relation to ECG	P wave	T wave
Response To exertion	Prominence noted	Not significant

The v wave represents atrial filling (atrial diastole) and occurs during ventricular systole. The height of the v wave is determined by right atrial compliance as well as the volume of blood returning to the right atrium either antegrade from the caeve or retrograde through an incompetent tricuspid valve.

The descents or troughs of the jugular venous pulse occur between the "a" and "c" wave ("x" descent), between the "c" and "v" wave ("x' descent), and between the "v" and "a" wave ("y" descent). x wave (descent): Due to continued atrial relaxation.

x' wave (descent): due to descent of floor of right atrium (tricuspid valve) during right ventricular systole and continued atrial relaxation. The y descent represents the abrupt termination of the downstroke of the v wave during early diastole after the tricuspid valve opens and the right ventricle begins to fill passively (Fig 5).

Fig 5: Correlation of JVP with different phases of cardiac cycle



Normally the y descent is neither as brisk nor as deep as the x descent. Usually, the descents in the jugular venous pulse are brisk but not excessively rapid, and the x descent is characteristically deeper than they descent.

RESPIRATORY VARIATION IN LEVEL AND WAVE PATTERN

Normally, the mean venous pressure falls during passive inspiration as phasic flow of blood occurs in the superior vena cava and the right ventricle accommodates this increased venous return.

HEPATO-JUGULAR REFLUX

The examiner applies firm but persistent pressure over the liver for 10 seconds while observing the mean jugular venous pressure. Normally there is either no rise or only a transient (i.e., 2 to 3 sec) rise in mean jugular venous pressure.

VENOUS HUM

Continuous bruit over neck veins (normally noiseless) due to increased velocity of blood flow or decreased viscosity of blood. This may be physiological in children and pregnancy.

LIVER SIZE AND PULSATIONS

Normally liver pulsations are not felt. In an infant, the liver is the only guide to the recognition of elevated right atrial pressure as the JVP is difficult to delineate.

- 'a' wave: clinically appears after S1
- 'v' wave: clinically appears after S2

NORMAL JVP

The normal mean jugular venous pressure, determined as the vertical distance above the midpoint of the right atrium, is 6 to 8 cm H₂O. Other features during respiration, wave, effect of hepatojugular reflex is mentioned above.

ABNORMAL JVP

Level - 6 to 8 cm H₂O. Deviations from this normal range reflect either hypovolemia (i.e., mean venous pressure less than 5 cm H₂O) or impaired cardiac filling (i.e., mean venous pressure greater than 9 cm H₂O).

Causes of elevated JVP (Jugular venous distension):

- Right ventricular failure
- Pericardial compression (constriction/tamponade)
- Tricuspid stenosis
- Superior vena cava (SVC) obstruction – no pulsations
- Circulatory overload
- Renal failure
- Excessive fluid administration
- Atrial septal defect with mitral valve disease

ABNORMAL WAVES

ABNORMALITIES IN SYSTOLIC WAVES

A. Giant “a” waves (Venous Corrigan) are classically described as "leaping to the eye" and are greater in height than usually perceived. There are only two causes of giant a waves:

1. RV level - Decreased right ventricular compliance due to pulmonary valve stenosis, chronic obstructive pulmonary disease with associated pulmonary hypertension, or restrictive cardiomyopathy, severe aortic stenosis, acute pulmonary embolism, acute tricuspid regurgitation.
2. Tricuspid level - Tricuspid stenosis.

TRICUSPID STENOSIS - A relatively modest diastolic pressure gradient (i.e., a mean gradient of only 5 mm Hg) is usually sufficient to elevate mean right atrial pressure to levels that result in systemic venous congestion and, unless sodium intake has been restricted or diuretics have been given, is associated with jugular venous distention, ascites, and edema. The severity of these symptoms, which are secondary to an elevated systemic venous pressure, is out of proportion to the degree of dyspnea. Some patients complain of a fluttering discomfort in the neck, caused by giant a waves in the jugular venous pulse. In the presence of sinus rhythm, the a wave in the jugular venous pulse is tall, and a presystolic hepatic pulsation is often palpable. The y descent is slow and barely appreciable.

B. Cannon "a" waves - Cannon "a" waves are abnormalities in the a wave that occur when right atrial contraction takes place against a closed tricuspid valve as in complete heart block. If atrial contraction occurs at an appropriate time during a ventricular ectopic beat, however, cannon "a" waves may also be observed.

If irregular cannon "a" waves are observed in a patient with tachycardia, the dysrhythmia is likely to be ventricular tachycardia.

1. Regular cannon waves: Junctional rhythm, Ventricular tachycardia 1:1 retrograde conduction, Iso-rhythmic AV dissociation
2. Irregular cannon waves: Complete heart block, Ventricular tachycardia, Ventricular ectopy, Ventricular pacing, Classic AV dissociation

Table 2: Differences between Cannon and giant "a" waves

Giant "a" waves	Cannon "a" waves
Uniform in height	Variable in height
Observed during each cardiac cycle	Occur sporadically because of the variable relationship of atrial contraction to ventricular systole.

- C. Flutter" or fibrillatory waves - in the presence of atrial flutter, the normal a wave is replaced by "flutter" or fibrillatory waves. The latter are generally of a lower amplitude and, because of their regularity (i.e., about 250 to 300/min), are very difficult to observe.

D. Absent ‘a’ waves - If the patient has atrial fibrillation, there can be no organized atrial activity, and the "a" wave of the jugular venous pulse is lost altogether.

- Atrial fibrillation (AF)
- Post DC conversion of AF
- Sino ventricular conduction in hyperkalemia

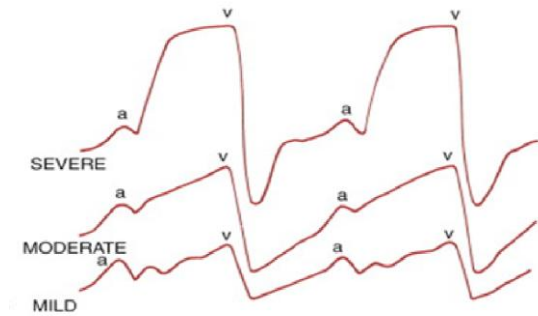
E. "CV" waves – are seen in

- Right ventricular failure
- Tricuspid regurgitation - Unlike the normal jugular venous contour, patients with marked tricuspid insufficiency have "c" and "v" waves that merge to produce a broad positive wave

called a "cv" wave, which occurs simultaneously with the carotid pulse (Fig: 6).

- Atrial septal defect with or without mitral regurgitation

Fig 6: JVP in different severity of TR.



TRICUSPID REGURGITATION: There is jugular venous distention, the normal x and x' descents disappear, and a prominent systolic wave, i.e., a c-v wave (or s wave), is apparent. The descent of this wave, the y descent, is sharp and becomes the most prominent feature of the venous pulse (unless there is coexisting TS, in which case it is slowed). A venous systolic thrill and murmur in the neck may be present in patients with severe TR. Occasionally, patients have throbbing pulsations in the neck, which intensify on effort and are due to jugular venous distention; and systolic pulsations of the eyeballs have also been described.

F. Diminished 'v' wave – causes are
Hypovolemia
Venodilators

G. Single wave

'a' and 'v' wave merge: Heart rate > 120/min
early 'v' wave with obliterated 'x' wave: Severe chronic tricuspid regurgitation, acute tricuspid regurgitation.

ABNORMALITIES IN DIASTOLIC DESCENTS

A. Prominent 'x' wave

- Cardiac tamponade

B. Absent 'x' wave - Is due to failure of atrial pressure to fall

1. Atrial fibrillation
2. Severe chronic tricuspid regurgitation
3. Acute tricuspid regurgitation
4. Constrictive pericarditis

C. Rapid 'y' descent

Causes of prominent 'v' wave

Constrictive pericarditis (Friedrich's sign)

D. Slow y descent

1. Tricuspid stenosis
2. Right atrial myxoma (or thrombus).
3. Constrictive pericarditis with isolated pericardial constriction of the right atrioventricular groove
4. Pericardial tamponade
5. Tension pneumothorax

When right ventricular filling becomes hindered (i.e., in the setting of constrictive pericarditis or right ventricular failure), these descents become unusually rapid.

In such instances, the contour of the jugular venous pulse may be described as "flicking," and the x and y descents may be said to describe a "W" or "M" shaped pattern. In constrictive pericarditis, the y descent is often deeper than the x descent (Friedreich's sign) (Fig 7, 8, 9). Drawing of jugular venous pulse showing rapid x and y descents as may be noted in constrictive pericarditis.

Fig7: JVP in constrictive pericarditis-along with heart sounds.

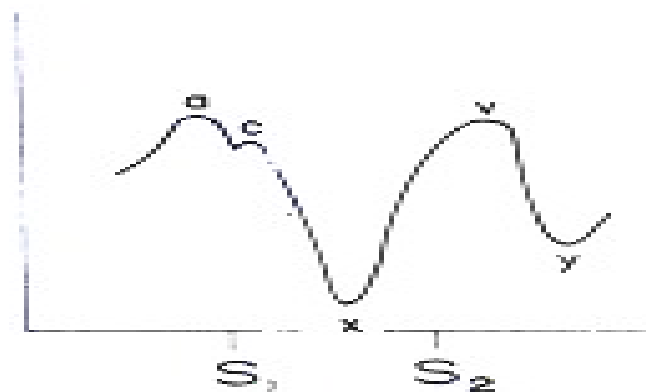


Fig 8: JVP in constrictive pericarditis and tamponade.

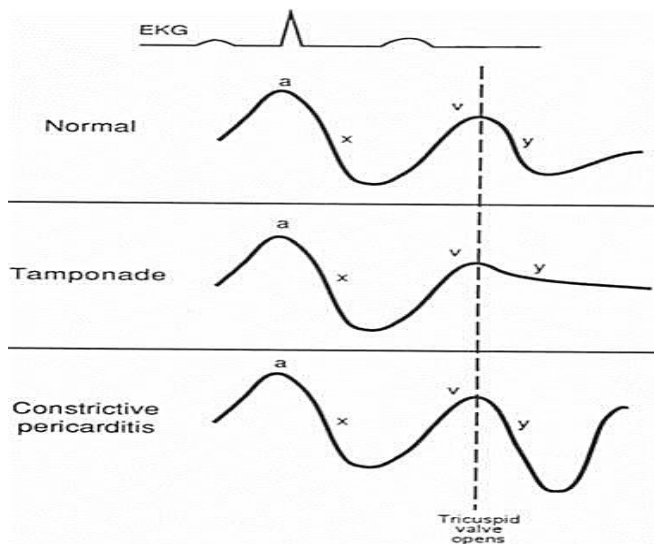
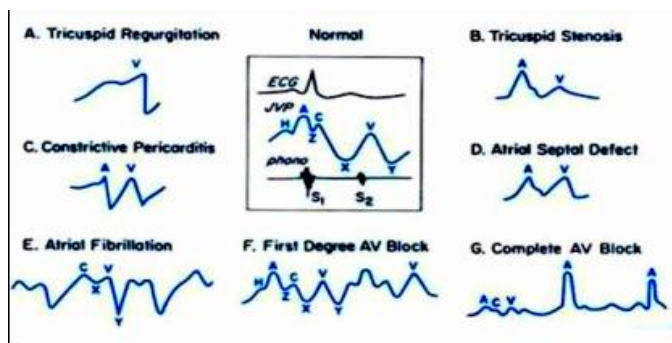


Fig 9: Graphic representation of JVP in different heart diseases.



CONSTRUCTIVE PERICARDITIS: High systemic venous pressure and reduced cardiac output result in compensatory retention of sodium and water by the kidneys. Inhibition of atrial natriuretic peptide also contributes to renal sodium retention and further exacerbates increases in systemic venous and left-sided filling pressures. [Atrial fibrillation and tricuspid regurgitation, which further exacerbate venous pressure elevation. Physical findings include markedly elevated jugular venous pressure with a prominent, rapidly collapsing y descent. This, combined with a normally prominent x descent, results in an M- or W-shaped venous pressure contour. At the bedside, this is best appreciated as two prominent descents with each cardiac cycle. In patients in atrial fibrillation, the x descent is lost, leaving only the prominent y descent.

The latter is difficult to distinguish from tricuspid regurgitation, which, as noted earlier, may itself occur as a consequence of constrictive pericarditis. Kussmaul sign, an inspiratory increase in systemic venous pressure, is usually present, or the venous pressure may simply fail to decrease on inspiration. Kussmaul sign reflects loss of the normal increase in right heart venous return on inspiration, even though tricuspid flow increases. These characteristic abnormalities of the venous waveform contrast markedly with those in tamponade. In shock, Because of the poor correlation between left ventricular filling pressure and mean right atrial pressure, assessment of systemic (even central) venous pressure is of limited value as a guide to fluid therapy.

JVP IN CARDIAC TAMPONADE - A valuable and reproducible sign of pericardial tamponade is a narrowing of the pulse pressure. An elevation of the central venous pressure often accompanies rapid and cyclic hyper resuscitation with crystalloid solutions, but in such instances a widening of the pulse pressure occurs. In addition to elevated and equal intracavitary filling pressures, markedly reduced transmural filling pressures, and small cardiac volumes, two other hemodynamic abnormalities are characteristic of tamponade. One is loss of the y descent of the right atrial or systemic venous pressure . The x and y descents of the venous pressure waveform correspond to periods when flow is increasing. Loss of the y descent has been explained on the basis of the concept that total heart volume is fixed in severe tamponade. Thus blood can enter the heart only when blood is simultaneously leaving. The right atrial y descent begins when the tricuspid valve opens (i.e., when blood is not leaving the heart). Thus no blood can enter the heart, and the y descent is lost. In contrast, the x descent occurs during ventricular ejection. Because blood is leaving the heart, venous inflow can increase and the x descent is retained. Loss of the y descent can be difficult to discern at the bedside but is easily appreciated in recordings of systemic venous or right atrial pressure and provides a useful clue to the presence of significant tamponade.

In tamponade, in contrast to constrictive pericarditis, the normal inspiratory increase in systemic venous return is

retained. Therefore the normal decline in systemic venous pressure on inspiration is present (Kussmaul sign is absent). triad of hypotension, muffled heart sounds, and elevated jugular venous pressure remains a useful clue to the presence of severe tamponade. Tamponade can be confused with anything that causes hypotension, shock, and elevated jugular venous pressure including myocardial failure, right heart failure caused by pulmonary embolus or other causes of pulmonary hypertension, and RV MI. In a cardiac tamponade patient Filling pressures that remain elevated after pericardiocentesis and the appearance of venous waveforms typical of constriction (rapid x and y descents) indicate coexistent constriction.

ABNORMAL RESPIRATORY VARIATION IN LEVEL AND WAVE PATTERN

Inspiratory Rise In Mean Venous Pressure

When constrictive pericarditis is present, phasic blood flow does not occur in the superior vena cava. During inspiration the mean venous pressure rises (Kussmaul's sign). This sign is sensitive but not specific for constrictive pericarditis. May also be observed in right ventricular infarctions or restrictive cardiomyopathies or Cardiac tamponade.

RV Infarct

Includes elevated right ventricular filling pressure; steep, right atrial y descent; and an early diastolic drop and plateau (resembling the square root sign) in the right ventricular pressure tracing. Moreover, the Kussmaul sign (an increase in jugular venous pressure with inspiration) and pulsusparadoxus (a fall in systolic pressure of greater than 10 mm Hg with inspiration) may be present in patients with right ventricular infarction. In fact, the Kussmaul sign in the setting of inferior STEMI highly predicts right ventricular involvement.

Significance of Inspiratory collapse of jugular veins

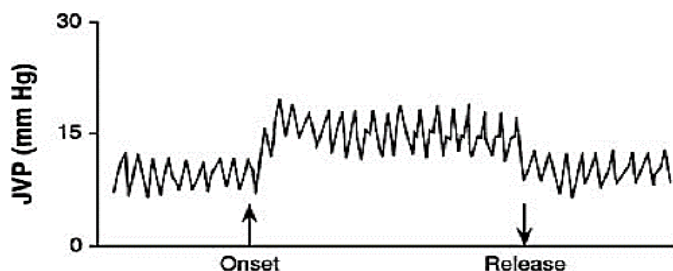
When evaluated in the supine position, distended neck veins that do not collapse indicate an abnormally elevated venous pressure. While visible veins that

collapse during deep inspiration or with a vigorous sniff suggest a normal JVP. Those that are not (or barely) visible that collapse indicates a low JVP. This methodology is applicable to most clinical situations.

ABNORMAL HEPATOJUGULAR REFLUX

After applying firm but persistent pressure over the liver for 10 seconds a sustained increase in the mean venous pressure until abdominal compression is released is abnormal and indicates impaired right heart function (positive test)(Fig 10).

Fig 10: HJR in impending CCF



Positive test is seen in early cardiac failure
 False positive: Valsalva (abdominal guarding), fluid overload
 False negative: SVC/IVC obstruction, Budd chiari syndrome

ABNORMAL VENOUS HUM

Pathological: Hyperkinetic states, Anemia, Thyrotoxicosis, Beriberi, Intracranial AV fistula.

ABNORMAL LIVER PULSATIONS AND SIZE

ACUTE HEART FAILURE

Hepatomegaly and splenomegaly can occur acutely in patients with AHF because of increased central venous pressure, and in these cases often results in significant tenderness, but it is more often the result of chronic systemic venous hypertension, where it is minimally tender.

MISNALLEOUS

IS JVP REFLECTS THE LEFT HEART PRESSURES?

YES, IT IS.

The jugular venous pressure provides the readiest bedside assessment of left ventricular filling pressure. An abnormally elevated jugular venous pressure is generally defined as >8 to 10 cm H₂O or >3 to 5 cm H₂O above the angle of Louis. Although the jugular venous pressure estimates RV filling pressure, it has a predictable relationship with PA wedge pressure. In 1000 consecutive patients with advanced heart failure undergoing right heart catheterization, Drazner and colleagues found that the RA pressure reliably predicted the PA wedge pressure ($r = 0.64$); the positive predictive value of an RA pressure >10 mm Hg for a PA wedge pressure >22 mm Hg was 88 percent. In addition, the PA systolic pressure could be estimated as twice the wedge pressure ($r = 0.79$). As noted previously, agreement among observers that venous pressure is elevated is modest (K statistic 0.31 to 0.69) and related in part to the experience of the observer as well as to the use of variable zero reference standards. The presence or absence of venous distention is more easily assessed than is the magnitude of venous pressure elevation. In 52 patients with chronic heart failure, Butman and colleagues reported that an elevated jugular venous pressure had a predictive accuracy of 67 percent for a pulmonary capillary wedge pressure >18 mm Hg (positive predictive value 95 percent, negative predictive value 47 percent). Unfortunately, studies are limited by small numbers of observations, bias by indication, and highly variable designs.

An elevated venous pressure has prognostic significance. Drazner and colleagues demonstrated that the presence of jugular venous distention at the time of enrollment in a large clinical heart failure trial (11 percent of the SOLVD treatment study participants), after adjusting for other markers of disease severity, predicted heart failure hospitalizations (RR 1.32, 95 percent CI 1.08 to 1.62), death from pump failure (RR 1.37, 95 percent CI 1.07 to 1.75), and death plus heart failure hospitalization (RR 1.30, 95 percent CI 1.11 to 1.53). They extended these observations to asymptomatic individuals enrolled in the SOLVD prevention study in which jugular venous distention was less common (1.7 percent of study population).

These findings are especially noteworthy in that the presence of jugular venous distention was reported in a "yes or no" format by the multiple investigators who participated in the trial.

Inducible jugular venous distention (abdominojugular reflux) suggests excessive RV preload, which is most commonly related to elevated left ventricular filling pressures but may also occur with other conditions (e.g., constrictive pericarditis, RV infarction). In patients presenting with dyspnea, the abdominojugular reflux is useful in predicting heart failure (LR + 6.0, 95 percent CI 0.8 to 51, LR - 0.78, 95 percent CI 0.62 to 0.98) and is suggestive of a PA wedge pressure >15 mm Hg (LR +6.7, 95 percent CI 3.3 to 13.4, LR - 0.08, 95 percent CI 0.01 to 0.52). The presence of jugular venous distention, either at rest or inducible, had the best combination of sensitivity (81 percent), specificity (80 percent), and predictive accuracy (81 percent) for elevation of the PA wedge pressure (>18 mm Hg).

Prognostication of elevated JVP:

The prognostic value of an S3 in chronic heart failure was established by the studies of Drazner and colleagues using the SOLVD treatment and prevention studies. The investigators found that an S3 predicted cardiovascular morbidity and mortality (Fig. 11-13). The relative risk for heart failure hospitalization and death in patients with an S3 in both the prevention and treatment cohorts was of comparable magnitude. These observations remained significant after adjustment for markers of disease severity and were even more powerful when combined with the presence of an elevated jugular venous pressure.

In determining mean jugular venous pressure, one assumes that the filling pressure of the right atrium and right ventricle mirror that of the left atrium and left ventricle. This relationship is usually correct. Thus, a mean jugular venous pressure greater than 10 cm H₂O usually indicates volume overload, while a low jugular venous pressure (i.e., less than 5 cm H₂O) usually indicates hypovolemia.

An elevated venous pressure has prognostic significance. The presence of jugular venous distention, either at rest or inducible, had the best combination of sensitivity (81 percent), specificity (80 percent), and predictive accuracy (81 percent) for elevation of the PA wedge pressure (>18 mm Hg).

But there are important, notable exceptions to this relationship. First, acute left ventricular failure may pressure without raising the mean right atrial and jugular venous pressures. Second, pulmonary hypertension, tricuspid insufficiency, or stenosis may be associated with elevated mean right atrial and jugular venous pressures while leaving the left heart pressures unaffected. In using the mean jugular venous pressure in clinical practice, the physician must correlate this bedside measurement with the other information gained from the history and physical examination.

significantly raise the pulmonary capillary wedge

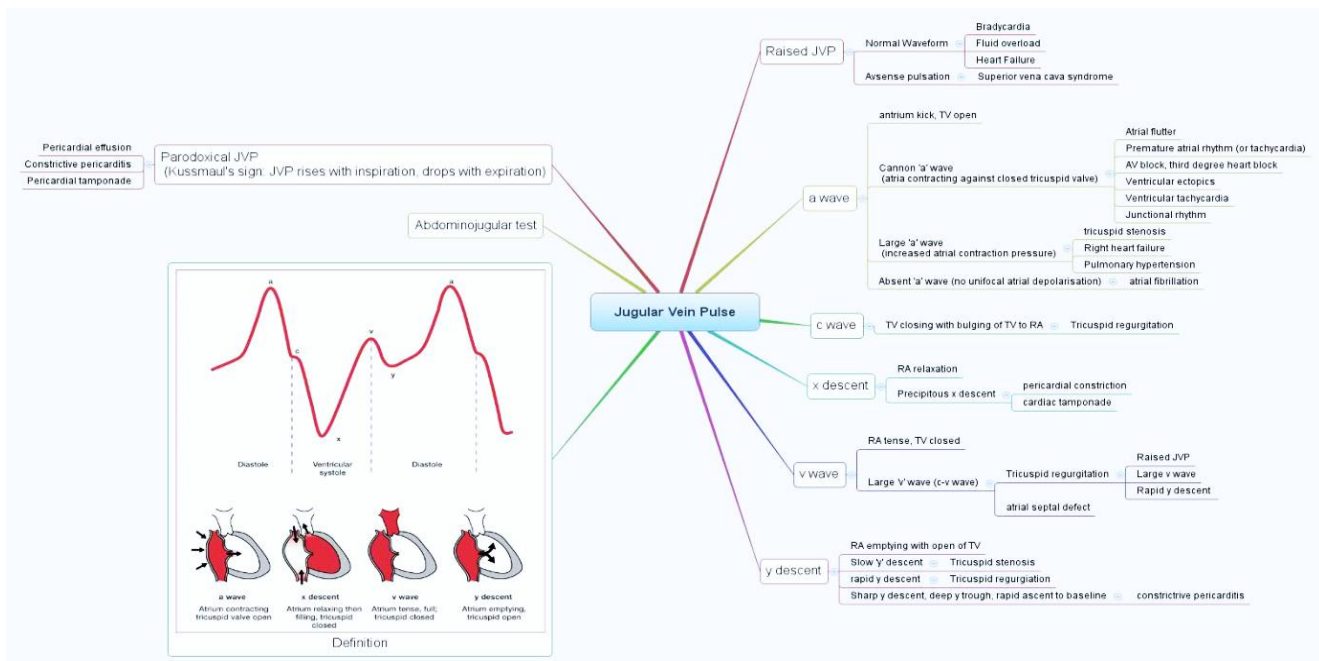
Elevation in Mean Venous Pressure without Distention in External Jugular Veins

Occurs in the patient with

1. Severe biventricular congestive heart failure
2. Constrictive pericarditis
3. Cardiac tamponade.

The cause of this dissociation is uncertain, although venoconstriction from the marked elevations in plasma catecholamine's that accompany these pathologic states.

Fig 10: Flow diagram of JVP



JVP IN DIFFERENT CONGENITAL HEART DISEASE

Atrial Septal Defect

There is "left atrialization" of the jugular venous pressure (A wave=V wave).

Pulmonary Stenosis

Patients with mild pulmonary valve stenosis have normal waves and therefore normal jugular venous pulsations. With more severe obstruction, the a wave

becomes progressively larger, and abnormal pulsations may be felt both in the jugular venous pulse and in the liver. In infants and children, jugular venous pulsations are often difficult to appreciate, even in the presence of large a waves.

After Font on surgery:

Physical examination in an otherwise uncomplicated patient reveals an elevated, usually nonpulsatile jugular venous pulse (10cm above the sternal angle and needed to provide the hydrostatic pressure to drive cardiac output through the pulmonary circulation). It has been

suggested that the exclusion of the right atrium from elevated systemic venous pressure (as in total cavopulmonary connection or extracardiac conduit) leads to a decrease in the incidence of atrial arrhythmias. Pulmonary Thromboembolism is increasingly recognized and will elevate central venous pressure.

EBSTEIN'S ANOMALY:

Physical examination typically reveals an unimpressive jugular venous pressure because of the large and compliant right atrium and atrialized right ventricle.

JVP IN MISNALLNEOUS HEART DISEASES

In pulmonary hypertension

Primary Pulmonary Hypertention-The clinical course of patients with IPAH can be highly variable. However, with the onset of overt right ventricular failure manifested by worsening symptoms and systemic venous congestion, patient survival is generally limited to approximately 6 months.

PULMONARY ARTERIAL HYPERTENSION

Patients with severe pulmonary hypertension may also have prominent v waves in the jugular venous pulse as a result of tricuspid regurgitation. The jugular venous pressure may also be difficult to assess in patients with COPD because of large swings in intrathoracic pressure. EISENMENGER SYNDROME - The jugular venous pressure in patients with Eisenmenger syndrome can be normal or elevated, especially with prominent v waves when tricuspid regurgitation is present.

IN MS - The jugular venous pulse usually exhibits a prominent a wave in patients with sinus rhythm and elevated pulmonary vascular resistance. In patients with AF, the x descent of the jugular venous pulse disappears, and there is only one crest, a prominent v or c-v wave, per cardiac cycle.

In STMI – RVMI

The jugular venous pulse is often normal in patients with acute myocardial ischemia but may reveal characteristic patterns with pericardial tamponade or

acute right ventricular dysfunction. Patients with STEMI and cardiogenic shock usually have elevated jugular venous pressure. In patients with STEMI, hypotension, and hypo perfusion (findings that may resemble those of patients with cardiogenic shock) but who have flat neck veins, it is likely that the depression of left ventricular performance may relate, at least in part, to hypovolemia. The differentiation can be made only by assessing left ventricular performance using echocardiography or by measuring left ventricular filling pressure with a pulmonary artery flotation catheter.

SVC obstruction

Physical findings include venous distension over the neck (66 percent) and chest wall (54 percent), facial edema (46 percent), plethora (19 percent), and cyanosis (19 percent). Symptoms may be exacerbated by lying in a supine position or bending forward.

In arrhythmias

In a patient with a wide complex tachycardia, the appreciation of cannon a waves in the jugular venous waveform identifies the rhythm as ventricular in origin.

FOCAL ATRIAL TACHYCARDIA

Physical findings during a variable rhythm include variable intensity of the first heart sound and systolic blood pressure as a result of the varying AV block and PR interval. An excessive number of a waves can be seen in the jugular venous pulse.

CONCEALED ACCESORY PATHWAT WITH SVT

Jugular venous pressure can be elevated (large A wave), but the waveform generally remains constant.

FIRST-DEGREE AV BLOCK

can be recognized by a long a-c wave interval in the jugular venous pulse and by diminished intensity of the first heart sound as the PR interval lengthens

PREMATURE VENTRICULAR COMPLEXES

The relationship of atrial to ventricular systole determines the presence of normal a waves or giant a waves in the jugular venous pulse, and the length of the PR interval determines the intensity of the first heart sound.

Normal Pregnancy

By the middle of the second trimester, the jugular venous pressure may be elevated, with brisk descents, because of the volume overload and reduced peripheral resistance.

Oedema Due To Hepatic Origin

Jugular venous pressure normal or low. Severe heart failure may cause ascites that may be distinguished from the ascites caused by hepatic cirrhosis by the jugular venous pressure, which is usually elevated in heart failure and normal in cirrhosis. Lower extremity edema in the absence of jugular venous hypertension may be due to lymphatic or venous obstruction or, more commonly, to venous insufficiency, as further suggested by the appearance of varicosities, venous ulcers (typically medial in location), and brownish cutaneous discoloration from hemosiderin deposition (eburnation).

Following Cardiac Surgery

Normally, the venous pressure should fall by at least 3 mmHg with inspiration. Kussmaul's sign is also a common, isolated finding in patients after cardiac surgery without other hemodynamic abnormalities.

ACKNOWLEDGEMENTS

To all cardiology teachers.

REFERENCES:

1. Ewy GA, Marcus FI. Bedside estimation of the venous pressure. *Heart Bull.* 1968;17:41-44.
2. Perloff JK. *Physical examination of the heart and circulation*, Philadelphia: W.B. Saunders, 1982.
3. Braunwald's *Heart Disease: A Textbook of Cardiovascular Medicine*, Single Volume: Expert Consult Premium Edition – Enhanced Online Features and Print, 10th Edition.
4. Perloff's *Clinical Recognition of Congenital Heart Disease*, 6th Edition Expert Consult - Joseph Perloff Ariane Marelli.
5. *Congenital Heart Disease in Adults* Hardcover, 3rd Edition - Perloff.
6. Moss & Adams' *Heart Disease in Infants, Children, and Adolescents, Including the Fetus and Young Adult* 9th Edition
7. *Harrison's Principles of Internal Medicine*- Dennis Kasper, Anthony Fauci, Stephen Hauser, Dan Longo, J. Larry Jameson, Joseph Loscalzo 19th edition.
8. Vinayak AG, Levitt J, Gehbach B, et al: Usefulness of the external jugular vein examination in detecting abnormal central venous pressure in critically ill patients. *Arch Intern Med* 2006; 166(19):2132-2137.
9. Cook DJ, Simel DL: The Rational Clinical Examination. Does this patient have abnormal central venous pressure?. *JAMA* 1996; 275(8):630-634.
10. McGee SR: Physical examination of venous pressure: A critical review. *Am Heart J* 1998; 136(1):10-18.
11. Ramana RK, Senegala T, Lichtenberg R: A new angle on the Angel of Louis. *Congest Heart Fail* 2006; 12(4):196-199.
12. Seth R, Magner P, Matziner F, vanWalraven C: How far is the sternal angle from the mid-right atrium? *J Gen Intern Med* 2002; 17(11):852-856.
13. Courtois M, Fattal PG, Kovacs Jr. SJ, et al: Anatomically and physiologically based reference level for measurement of intracardiac pressures. *Circulation* 1995; 92(7):1994-2000.
14. Drake JJ: Locating the external reference point for central venous pressure determination. *Nurs Res* 1974; 23(6):475-482.

15. Hurrell DG, Nishimura RA, Higano ST, et al: Value of dynamic respiratory changes in left and right ventricular pressures for the diagnosis of constrictive pericarditis. *Circulation* 1996; 93(11):2007-2013.
16. Wiese J: The abdominojugular reflux sign. *Am J Med* 2000; 109(1):59-61.
17. Butman SM, Ewy GA, Standen JR, et al: Bedside cardiovascular examination in patients with severe chronic heart failure: Importance of rest or inducible jugular venous distension. *J Am CollCardiol* 1993; 22(4):968-974.
18. Drazner MH, Hamilton MA, Fonarow G, et al: Relationship between right and left-sided filling pressures in 1000 patients with advanced heart failure. *J Heart LungTransplant* 1999; 18(11):1126-1132.
19. Drazner MH, Rame JE, Dries DL: Third heart sound and elevated jugular venous pressure as markers of the subsequent development of heart failure in patients with asymptomatic left ventricular dysfunction. *Am J Med* 2003; 114(6):431-437.